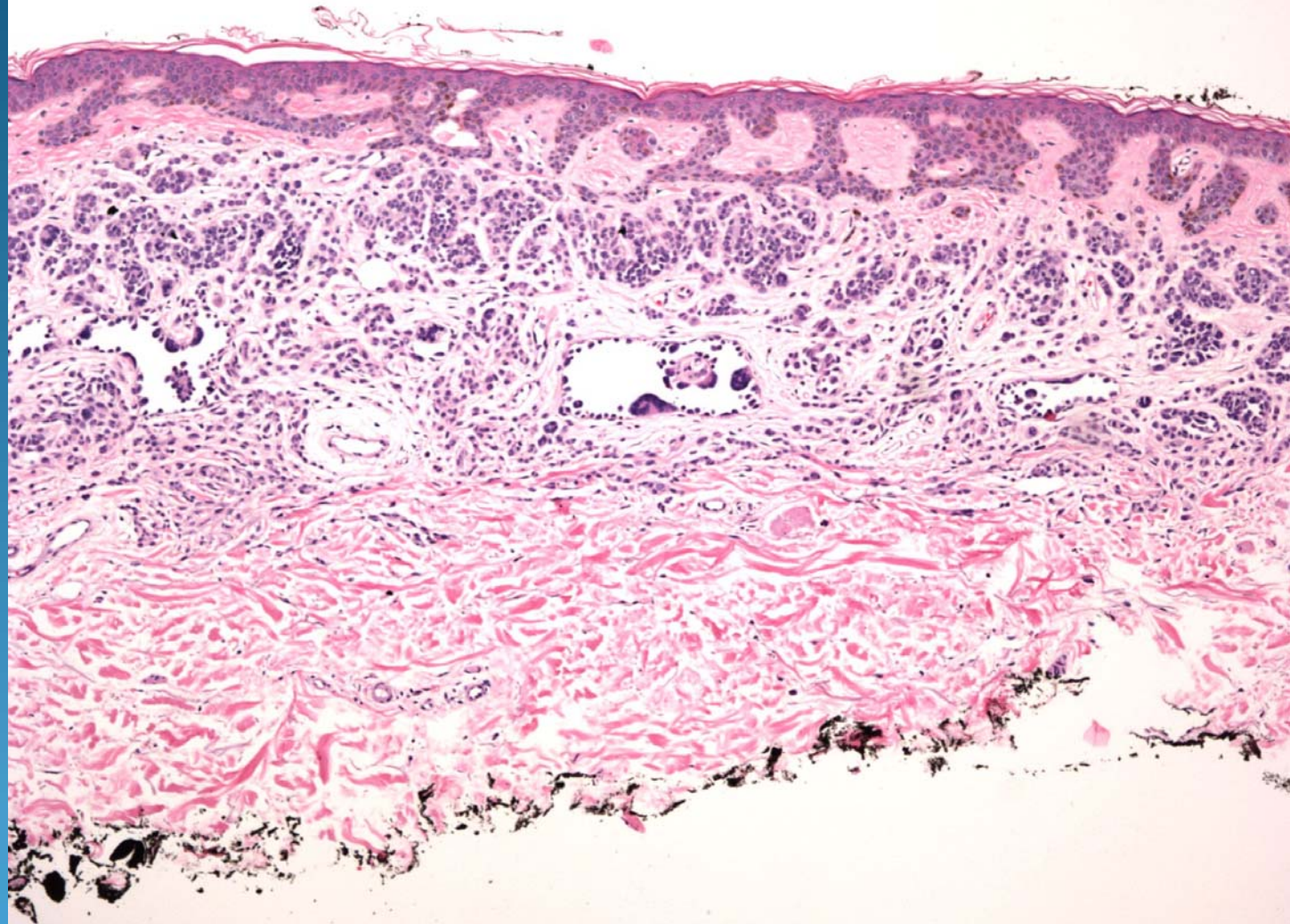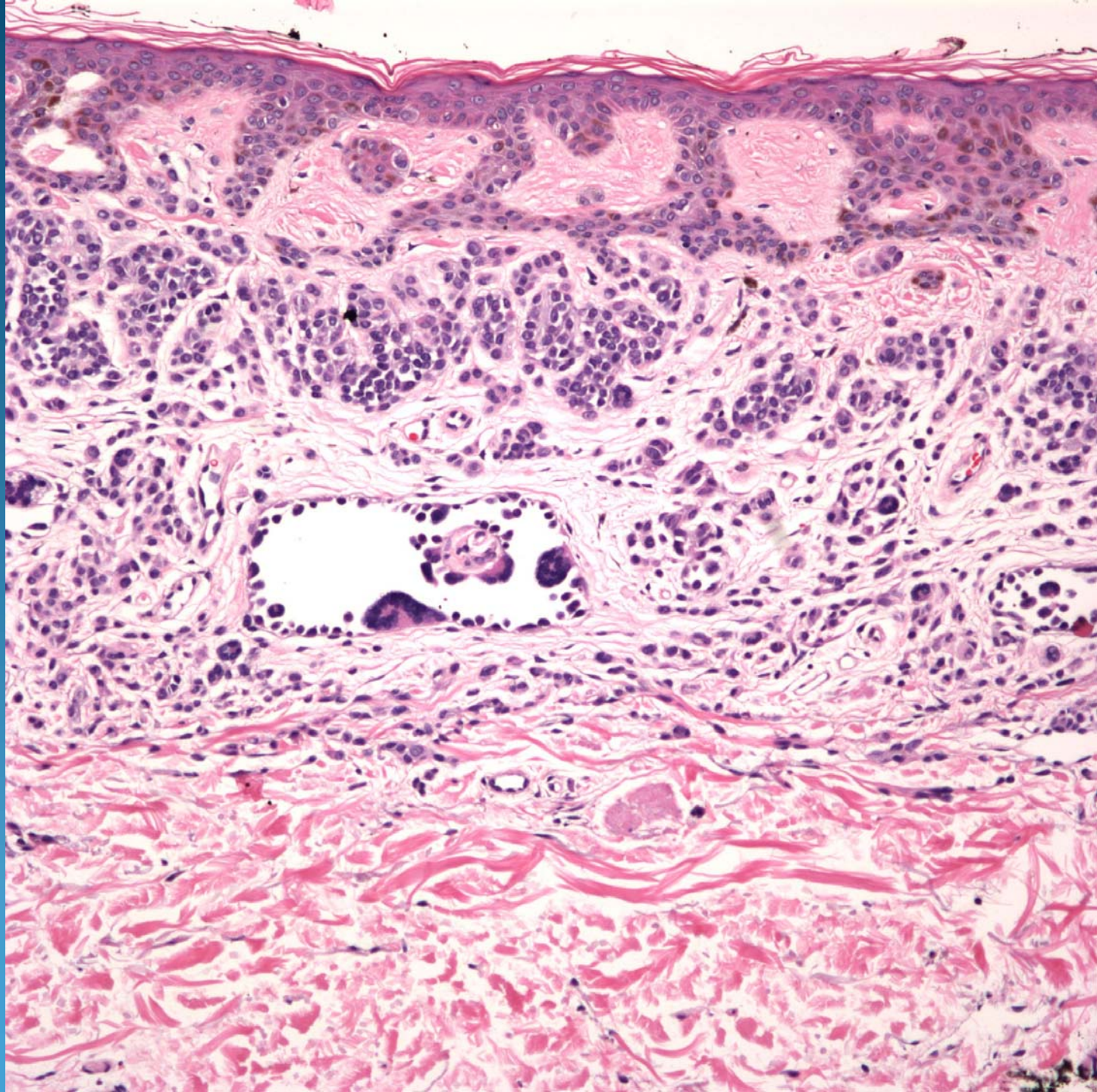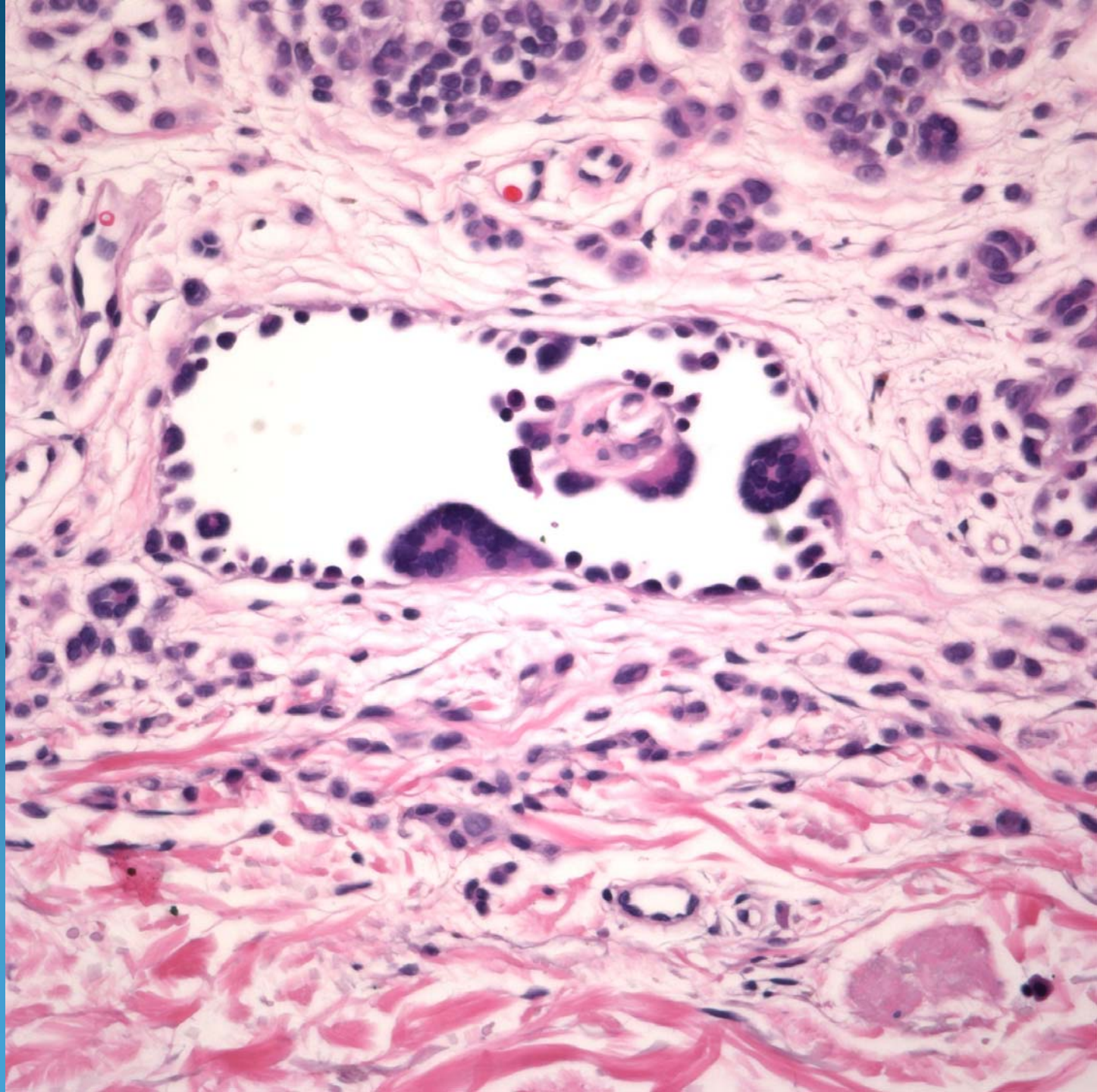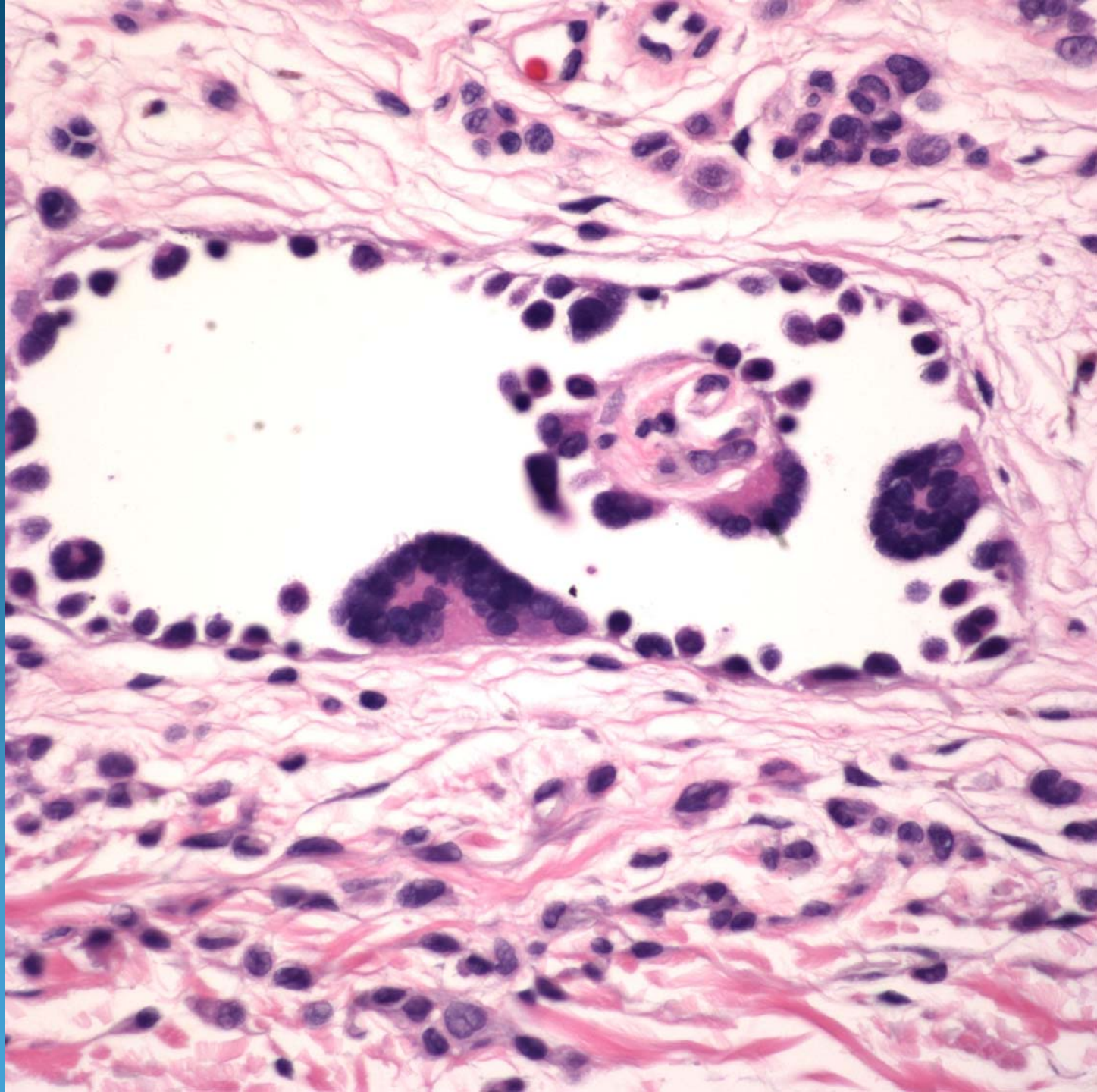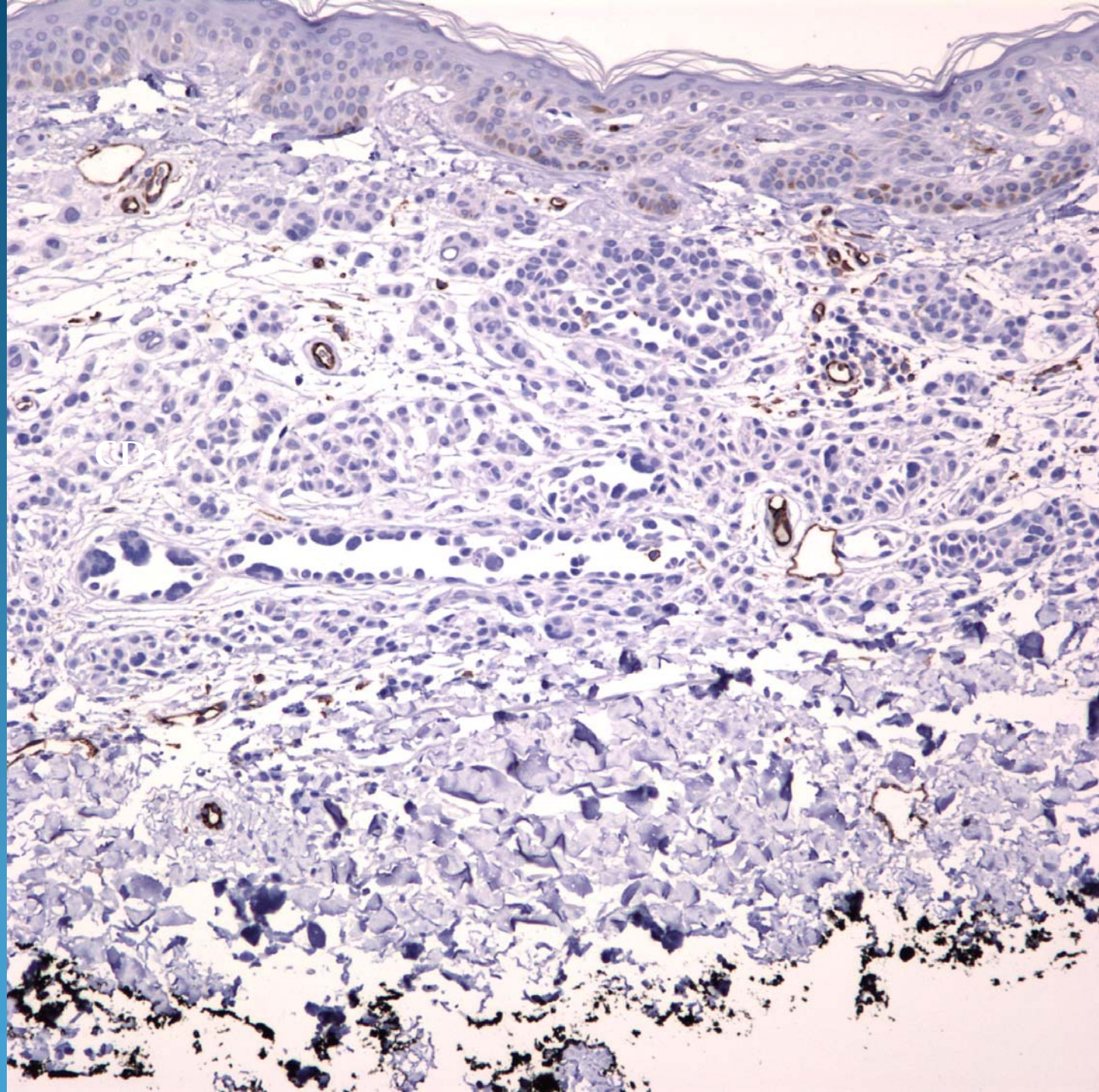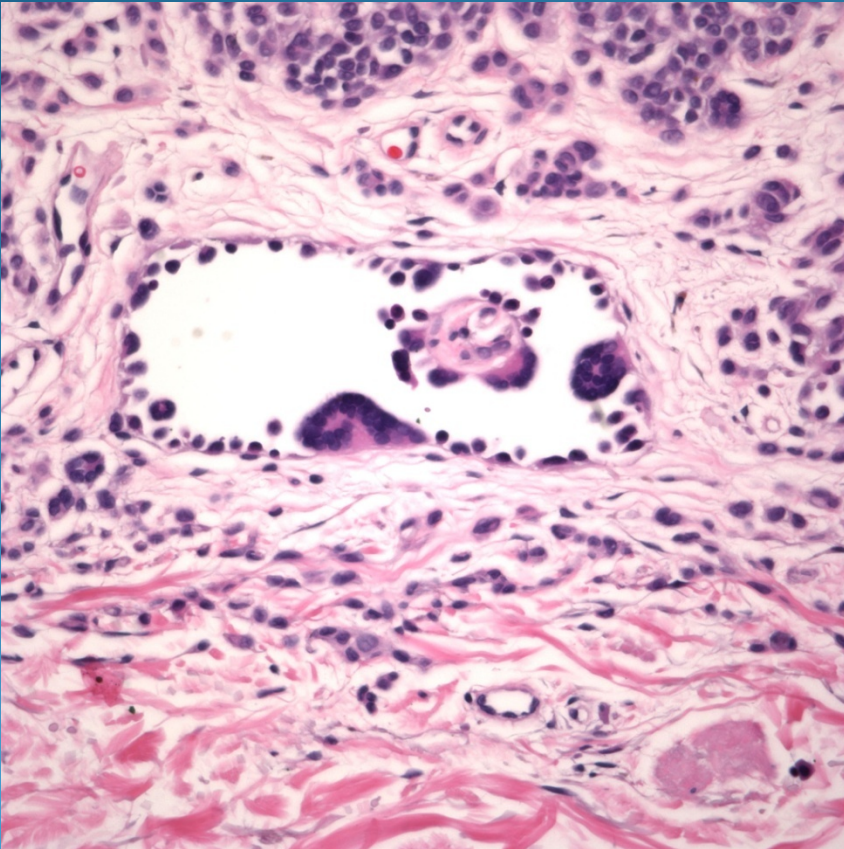


Intradermal melanocytic nevus,
with pseudovascular changes

Pearls



- Melanocytic nevi may exhibit many architectural patterns
- This pattern mimics a hobnail hemangioma
- Represent retraction around existing nests
- May confirm with absent staining for CD31